December 14-16, 2018
Seoul, South Korea
Day 1

APVRS SHOW DAILY

The Official Conference News of APVRS 2018

by pie magazine
posterior segment • innovation • enlightenment

Highlights

Do not miss the **Opening Ceremony** and the ***APVRS Tano Lecture*** *(Submacular Hemorrhage; Where Are We Now?* by Dr. Masahito Ohji) in the Auditorium at 15:30 - 16:00H today.

Published by:

media MICE
Nimble media makers for you

CEO & Publisher
Matt Young

Production & Circulation Manager
Hannah Nguyen

Chief Editor
Gloria D. Gamat

Associate Editor
Brooke Herron

Project Manager
Ruchi Mahajan Ranga

Publications & Digital Manager
Alex Young

Graphic Designers
Winson Chua
Edison Tan

Photographer
Dwayne Foong

Writers
Hazlin Hassan
Joanna Lee
John Butcher

Media MICE Pte. Ltd.
6001 Beach Road, #19-06
Golden Mile Tower,
Singapore 199589
Tel: +65 8186 7677
Fax: +65 6298 6316
Email: enquiry@mediamice.com
www.mediaMICE.com

www.piemagazine.org

APVRS 'Goes for the Gold' in Seoul

by Brooke Herron

The team at *PIE Magazine* has one thing on its collective mind: Gold. And not 'make-you-rich' gold (although we like that too), we're talking about the 'gold standard' . . . meaning the best current standards for posterior segment conditions and treatments.

With that said, the 12th meeting of the Asia-Pacific Vitreo-retina Society (APVRS), held in conjunction with the 34th meeting of the Korean Retina Society (KRS), is bound to be a 'golden' congress. So, in the spirit of 'going for the gold', we've uncovered a 'goldmine' of informative sessions and symposiums, free papers and posters/e-posters from the region's leading retina experts.

"The 12th APVRS Congress has invited renowned speakers and moderators, not just from the Asia-Pacific region, but also from around the world, in various subspecialties ranging from age-related macular degeneration (AMD) and polypoidal choroidal vasculopathy (PCV), diabetic macular edema (DME), pathological myopia, retinal dystrophy, intraocular tumors, uveitis, to ocular trauma," said Dr. Won Ki Lee, president of the 12th APVRS Congress and president of the Korean Retina Society. "The distinguished speakers will deliver their presentations on diagnoses, therapeutics, imaging modalities or operation procedures, which no doubt will lead to extensive discussion among colleagues in the vitreo-retinal field."

In addition to discussing the current gold standard, APVRS also looks toward raising that bar in the future. In fact, this year's congress also includes a symposium on "big data," which according to Dr. Paisan Ruamviboonsuk, has recently sparked tremendous interest in both the medical and non-medical fields.

Cont. on Page 3 >>

Photo of the Day

Seoul snowfall can't keep us away! We look forward to reporting on gold standard treatments at APVRS, Day 1.

Bayer

For Healthcare Professionals Only

In treatment-naïve patients…

START STRONG STAY STRONG[1-4]

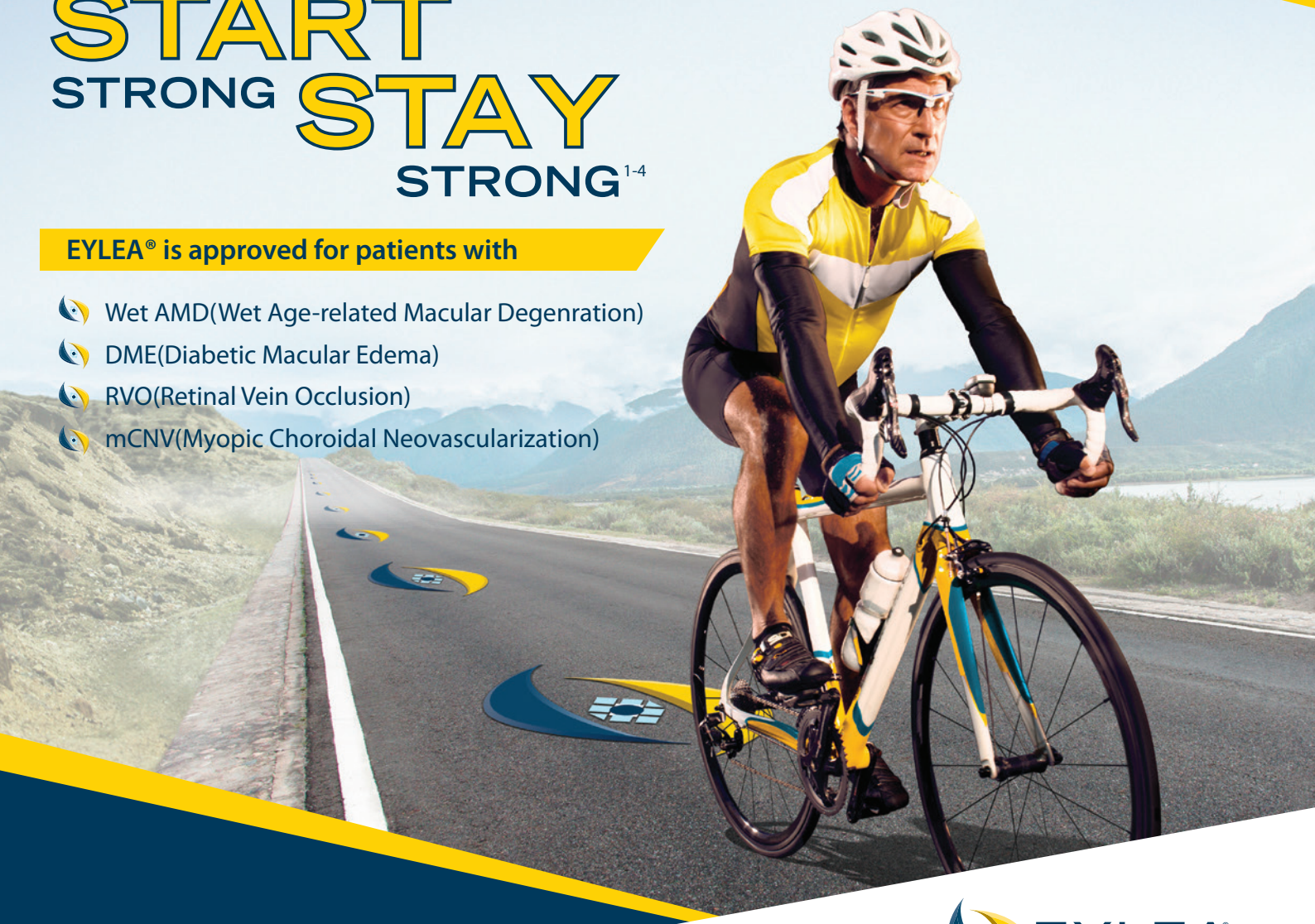

EYLEA® is approved for patients with

- Wet AMD(Wet Age-related Macular Degenration)
- DME(Diabetic Macular Edema)
- RVO(Retinal Vein Occlusion)
- mCNV(Myopic Choroidal Neovascularization)

EYLEA®
(aflibercept solution for injection)

EYLEA® (Aflibercept) is an intravitreal anti-VEGF agent that has been bioengineered to have strong, broad, and long-lasting activity[5-7]

wet AMD (wet age-related macular degeneration), DME (diabetic macular edema), BRVO (branch retinal vein occlusion), mCNV (myopic choroidal neovascularization)

[Product Name] EYLEA® injection **[Composition]** 1 vial(0.278 ml) containing aflibercept 11.120 mg **[Indications, Dosage and Administration]** This drug is for intravitreal injection. It must only be administered by a qualified physician experienced in administering intravitreal injections. In general, adequate anesthesia and asepsis, including topical broad spectrum microbiocide (e.g., povidone iodine), have to be ensured. Immediately following the intravitreal injection, patients should be monitored for elevation in intraocular pressure. Each vial should only be used for the treatment of a single eye. After injection any unused product must be discarded. The injection volume of this drug is 2mg (equivalent to 50 microliters). **1. Treatment of neovascular (wet) age-related macular degeneration** : This drug is initiated with one injection per month for three consecutive months, followed by one injection every 2 months. There is no requirement for monitoring between injections. Long term (after the first 12 months of treatment), it is recommended that patients continue to treated with this drug every 2 months. **2. Treatment of visual impairment due to macular edema secondary to retinal vein occlusion (branch RVO or central RVO)** : After the initial injection, treatment is given monthly. The interval between two doses should not be shorter than one month. If visual and anatomic outcomes indicate that the patient is not benefiting from continued treatment, Eylea should be discontinued. If there is no improvement over the course of the first three injections in case of CRVO patient, continued treatment is not recommended. Monthly treatment continues until maximum visual acuity is achieved and/or there are no signs of disease activity. Three or more consecutive, monthly injections may be needed. The monitoring and treatment schedule should be determined by the treating physician based on the individual patient's response. **3. Treatment of visual impairment due to diabetic macular edema.** : The recommended dose for EYLEA is 2 mg administered by intravitreal injection monthly for the first 5 consecutive doses, followed by one injection every 2 months **4. Treatment of visual impairment due to myopic choroidal neovascularization** : After initial injection, additional doses should be administered only if visual and anatomic outcomes indicate that the disease persists. The interval between two doses should not be shorter than one month. If visual and anatomic outcomes indicate that the patient is not benefiting from continued treatment, Eylea should be discontinued. The monitoring schedule should be determined by the treating physician. For further information about Dosage and Administration, please see the full Eylea® product information **[Contraindication] 1. Contraindications** :1) Ocular or periocular infection 2) Active severe intraocular inflammation 3) Known hypersensitivity to any ingredient of this drug **2. Special precautions** :1) Intravitreal injection-related reactions. Intravitreal injections, including those with Eylea, have been associated with endophthalmitis, intraocular inflammation, rhegmatogenous retinal detachment, retinal tear and iatrogenic traumatic cataract. Increases in intraocular pressure have been seen within 60 minutes of an intravitreal injection, including with this drug. 2) Arterial thromboembolic events (ATE) **3. Adverse Reactions** :Very common (≥1/10): Conjunctival hemorrhage, Eye pain, Common (≥1/100 ~ <1/10): Retinal pigment epithelial tear, Detachment of the retinal pigment epithelium, Cataract, Cataract cortical, Cataract nuclear, Cataract subcapsular, Corneal erosion, Corneal abrasion, Intraocular pressure increased, Vision blurred, Vitreous floaters, Vitreous detachment, Injection site pain, Foreign body sensation in eyes, Lacrimation increased, Eyelid edema, Injection site hemorrhage, Punctate keratitis, Conjunctival hyperemia, Ocular hyperemia **[Ethical Drug] [Imported and Marketed by]** Bayer Korea Ltd. Korea **[The latest revision date]** 02-May-17 **For further detailed information, please refer to the full Eylea® local product information or Bayer Korea website, http://www.bayer.co.kr/**

Bayer Korea Ltd.
SamSung Boramae Omni Tower, 23 Boramae-ro 5-gil, Dongjak-gu, Seoul 07071, Korea
Tel +82 2 829 6600 I http://www.bayer.co.kr/

Reference:

1. Heier JS et al. *Ophthalmology* 2012;119(12):2537-2548
2. Korobelnik JF et al. *Ophthalmology* 2014;121(11):2247-54
3. Kaiser PK et al. *Ophthalmology Retina* 2017;1:304-313
4. Heier JS et al. *Ophthalmology* 2016;123:2376-2385
5. Papadopoulos N, et al. *Angiogenesis*. 2012;15:171-185
6. Stewart MW. *Br J Ophthalmol*. 2012;96:1157-1158
7. Fauser S et al. *Am J Ophthalmol.* 2014 Sep;158(3):532-6

Cont. from Page 1 >>

"Harnessing big data through analytics with combination of artificial intelligence (AI) and machine learning may yield invaluable answers to epidemiologic, basic research, clinical practice questions, etc., and hence drive improvements in patient care. These innovative approaches will be an enlightening adventure for both comprehensive ophthalmologists and retinal specialists," said Dr. Ruamviboonsuk, who serves as the chair of the scientific program committee.

> "Harnessing big data through analytics with combination of artificial intelligence (AI) and machine learning may yield invaluable answers to epidemiologic, basic research, clinical practice questions, etc.."
>
> **– Dr. Paisan Ruamviboonsuk**

Invited Symposiums Strike Gold

This year, more than 500 abstracts were submitted for free paper and poster consideration. These – along with the invited symposiums and award lectures – create a truly golden scientific program. Here's a sneak peek of some of the symposia.

Retinal Vascular Disease. Delve deep into the management of retinal vascular diseases with this symposium. Topics include the role of diagnostic imaging tools (like wide-field imaging, optical coherence tomography angiography); the impact of AI; and advances in imaging and treatment of macular telangiectasias. In addition, trial-based and real-world treatment strategies (including anti-VEGF injections, steroid implants and lasers) will be presented.

2018-12-14 | 10:30-12:00
Ballroom 202-203

Controversies in Retina. Explore challenging and controversial issues faced by posterior segment surgeons in this symposium. Covering a range of topics, expect to hear about the latest diagnostic and surgical imaging instrumentation; micropulse lasers; treatment options for proliferative diabetic retinopathy (PDR); pros and cons of surgical techniques for floaters and myopic traction maculopathy; and the impact of AI in ophthalmology.

2018-12-14 | 13:40-15:10
Auditorium

Diabetic Retinopathy Symposium: DRCR.net. Sponsored by the National Institutes of Health, the DRCR Network is dedicated to multi-center clinical research of diabetic retinopathy, macular edema, as well as other retinal diseases. During this symposium, recent findings for the management of diabetic macular edema and PDR will be highlighted, with specific relevance to Asian populations.

2018-12-15 | 10:30-12:00
Auditorium

Latest Advancement in Macular Intervention. This session explores innovations in surgical retina, with insights into stem cell implantation, new surgical technologies and the Argus II retinal prosthesis – all potential armamentarium additions to enhance patient care.

2018-12-15 | 10:30-12:00
Ballroom 104 - 105

Big Data and Epidemiology. As mentioned by Dr. Ruamviboonsuk, this symposium will focus on combining big data with AI and machine learning to allow rapid analysis of large amounts of data. This has potential applications in traditional epidemiology, including use of "real world" surveys, cohort studies, genetic epidemiology and statistical modeling.

2018-12-16 | 08:30-10:00
Ballroom 202-203

Management of Anterior Segment Surgery Complications. Suitable for all ophthalmologists, especially trainees, vitreoretinal surgery fellows and general ophthalmologists, this symposium covers common anterior segment surgery complications that affect the posterior and surgical management options.

2018-12-16 | 10:30-12:00
Ballroom 202-203

"Since our meeting last year, the field of vitreoretinal diseases has continued to evolve with medical and surgical treatment options and exciting research," said Dr. Ruamviboonsuk. "With that in mind, the Scientific Program Committee comprising Asia-Pacific, international, and local Korean coordinators, has worked diligently to provide a remarkable range of topics that cover many key issues and major challenges in vitreoretinal practice in the world today."

In addition to the congress's noteworthy symposiums, free paper sessions and posters, attendees should also plan to attend the prestigious award lectures – and this year, another has been added: the Hyung-Woo Kwak Lecture. This is in remembrance of Prof. Kwak, a pioneer and inspiration in retinal research. This, along with the *Tano*, *Constable* and *International Award*-named lectures, are certain to be gold.

With all of these incredible opportunities for professional development, delegates should balance the scientific sessions with social engagements and entertainment – and thankfully, extra-curricular activities abound at APVRS 2018. The congress's social program provides ample prospects for networking and celebration, while the dynamic city of Seoul tempts visitors with a modern skyline, ancient temples and pagodas, delicious street food, and shopping.

Indeed, APVRS 2018 offers a goldmine of ophthalmic wisdom and skill sharing. Surely you will find each session truly valuable to your practice!

E-poster Sneak Peek:

Strike Gold Online at APVRS 2018

Do I see e-poster highlights?!

Fundus Images and Machine Learning for PDR Diagnosis

We are just beginning to understand the capabilities of machine learning and artificial intelligence in ophthalmic applications. Coupled with widefield fundus imaging, this technology has the potential to aid in diagnosis and improve patient care as a result.

In an e-poster titled *Accuracy of Ultra-WideField Fundus Ophthalmoscopy-Assisted Deep Learning, a Machine-Learning Technology, for Detecting Treatment-Naive Proliferative Diabetic Retinopathy*, Dr. Yuki Yoshizumi and colleagues investigated the detection of treatment-naïve proliferative diabetic retinopathy (PDR) using ultra-widefield fundus images with a deep convolutional neural network (DCNN), which is a machine learning technology.

The authors amplified 378 images (132 PDR and 246 non-PDR) and examined the area under the curve (AUC), sensitivity and specificity. They conducted a training with DCNN using the images and constructed a deep learning model which demonstrated high sensitivity (94.7%); high specificity (97.2%) and an AUC of 0.969. This led the investigators to conclude that PDR could be diagnosed using this approach.

An Unusual Case of a Large Choroidal Mass with Retinoschisis

The eye is both a delicate and intricate structure, which can lead to rare conditions and uncommon complications. Such is the case from Drs. Amelya Sari, Mutmainah Mayuuddin and Anggun Yudantha.

In an e-poster called *An Unusual Appearance of Large Choroidal Mass with Retinoschisis*, the authors present the case of a 62-year-old male. He had painless, blurry vision in his right eye and worsened visual acuity (hand movement), with no history of trauma or known malignancy.

Multiple screenings and tests were performed to assess the patient, including a funduscopic examination, which showed a clear vitreous and choroidal mass in superotemporal site, with orange-colored pigmentation and subretinal fluid surrounding the mass. Ocular ultrasonography showed high internal reflectivity, positive sound attenuation and acoustic solidity mass (size 9.7 x 10.9 x 5.0 mm), while optical coherence tomography on the macula demonstrated an elevated dome shape and splitting of the neurosensory retina. In addition, to rule out systemic cancer, an abdomen ultrasonography, chest x-ray and laboratory examination were performed. The patient also had an enlargement of the prostate, but laboratory markers showed a normal result and no malignancy was found by a urologist.

The authors suspected a benign choroidal mass with retinoschisis, along with hemangioma and nevus. The patient underwent ocular ultrasonography on a monthly interval and will be observed for three to six additional months (with ocular ultrasonography).

While this case is rare, the authors believe that all ophthalmologists should be aware that a large choroidal mass can lead to retinoschisis. In addition, they noted that the pathophysiology of retinoschisis caused by choroidal mass has never been reported, so it's important to use ancillary tests and clinical diagnosis to determine the cause.

Exploring Treat-and-Extend Regimens

Whether it's due to lack or access or prohibitive cost, compliance can be an issue for patients needing anti-VEGF therapy. Now, new treat-and-extend (T&E) regimens are showing promise to improve visual acuity, while reducing the number of injections needed – which may not only benefit patients, but physicians as well.

In this vein, Dr. Shih Jen Chen and colleagues shared results from the *PLANET STUDY*, in an e-poster titled: *Treat-and-Extend Intravitreal Aflibercept Use in Patients with Polypoidal Choroidal Vasculopathy (PCV) at 2 Years*.

Patients were randomized at week 12 to receive either intravitreal aflibercept (IVT-AFL) plus sham photodynamic therapy (PDT) or IVT-AFL plus rescue PDT. From weeks 52 to 96, patients not requiring rescue PDT could have their treatment intervals extended by one to two weeks at each visit (at the investigator's discretion.

apvrs Asia-Pacific Vitreo-retina Society

KRS 한국망막학회 The Korean Retina Society

The 12th APVRS

Congress of Asia-Pacific Vitreo-retina Society

SEOUL 2018

December 14 - 16

Coex Convention and Exhibition Center, Korea

10 out of 10 patients agree,
less is more when it comes to injections

Investigators found that in the IVT-AFL monotherapy and IVT-AFL plus rescue PDT groups, 57.9% and 51.9% reached treatment intervals extending to ≥10 weeks respectively; and 41.2% and 37.0% reached intervals of ≥12 weeks respectively. The mean best-corrected visual acuity (BCVA) change from baseline to week 96 was +11.1 and +11.0 ETDRS letters (≥10-week group) and +10.5 and +11.5 ETDRS letters (≥12-week group). The mean number of injections from week 52 to 96 was 4.1 and 4.4 (≥10-week group) and 3.9 and 4.2 (≥12-week group), respectively. Over 96 weeks, 15.9% patients in IVT-AFL monotherapy and 18.0% in IVT-AFL plus rescue PDT groups met the rescue criteria and gained +10.7 and +9.1 letters, respectively.

The most frequent ocular adverse events were conjunctival hemorrhage (6.4%) in IVT-AFL monotherapy group and dry eye (6.8%) in IVT-AFL plus rescue PDT group.

These results led the authors to conclude that at two years, patients receiving IVT-AFL monotherapy in a treat-and-extend (T&E) regimen had considerable improvements in visual and anatomical outcomes – similar to those with fixed dosing in year one – but with fewer injections. They concluded that "furthermore, IVT-AFL was noninferior to IVT-AFL plus rescue PDT in patients with PCV."

VR Surgery: Assessing Visual Outcomes from BRVO Complications

Branch retinal vein occlusion (BRVO) is a sight-threatening condition that can result in serious complications. Generally, neovascularization in BRVO develops six to 12 months after the disease's onset, and vitreous hemorrhage (VH) occurs two to three years later.

In an e-poster called *Vitreoretinal Surgery for Late Complications of Branch Retinal Vein Occlusion*, Drs. Faika Deddy and Ramzi Amin presented a case of a 59-year-old woman with VH secondary to BRVO with neovascularization elsewhere. They noted that vitrectomy is indicated when VH fails to resolve spontaneously

and laser treatment is considered for regression of the neovascularization.

The authors explained that once the blood cleared following vitrectomy, sectoral photocoagulation was used on the areas of neovascularization. Here, vitrectomy involves the removal of VH and releases the hyaloid from the fronds of retinal neovascularization ingrowth, while the goal of photocoagulation is to destroy ischemic retina and increase oxygen tension in the eye.

The patient's visual outcome was measured seven days after surgery. Visual acuity improved from hand movement to 0.3 logMAR, which led Drs. Deddy and Amin to conclude that vitrectomy combined with laser photocoagulation is safe and effective for intravascular reperfusion and produces significantly better visual acuity results.

Vitrectomy: Gas versus Silicone Oil Tamponade

Dr. Mohit Dogra and colleagues recently presented their findings from a retrospective interventional case series in an e-poster titled: *Comparison of Spectral-Domain Optical Coherence Tomography Findings between Eyes Undergoing Pars Plana Vitrectomy with Gas Versus Vitrectomy with Silicone Oil Tamponade for Primary Non-Complex Rhegmatogenous Retinal Detachment*.

In this series, patients with a history of trauma, previous retinal surgery/laser, giant retinal tears, choroidal detachment, choroidal colobomas, proliferative vitreoretinopathy greater than C2, or with follow-up of less than three months were excluded. In total, 40 eyes of 40 patients (14 females and 26 males) with a mean age of 54.69 were included.

The patients were split into two groups: 24 underwent pars plana vitrectomy (PPV) with gas and 16 had PPV with silicone oil. High-definition spectral-domain optical coherence tomography (SD-OCT) was performed at months one and three.

Of the 16 who had PPV with silicone oil, 8 eyes (50%) had foveal atrophy on SD-OCT at 3 months; 2 eyes (12.5%) had an epiretinal membrane; and the remaining 6 eyes (37.5%) had normal foveal contour. Of the 24 patients who had PPV with gas, only 2 eyes (8.3%) had foveal atrophy on SD-OCT; 21 eyes (87.5%) had normal foveal contour; and 1 eye (4.2%) had an epiretinal membrane with lamellar macular hole.

The authors concluded "when used as a tamponade agent, silicone oil causes greater damage to the photoreceptors, foveal atrophy and poorer recovery of vision as compared to gas. Its use should be reserved for repair of complex retinal detachments."

Traumatic Retinal Detachment: A Rare and Interesting Case

In this case report, Dr. Po-Chen Tseng illustrates why careful preoperative assessment is critical to saving sight. In his e-poster *Traumatic Retinal Detachment — Combined Retinal Dialysis and Giant Retinal Tear: A Case Report*, Dr. Tseng shares a case involving a 25-year-old, highly myopic (-11.75D) male who was struck in the left eye while playing basketball.

At presentation, the patient's best-corrected visual acuity (BCVA) was 20/20 (OD), 20/25 (OS) with normal intraocular pressure. A dilated fundus examination revealed draped vitreous opacity with clumps of pigment in upper quadrant, but without an obvious retinal break in the left eye.

However, five days later during his outpatient department follow-up, a dilated fundus examination showed scleral indentation, superotemporal retinal dialysis with vitreous base avulsion, and localized retinal detachment without macula involvement (OS). The patient was scheduled for scleral buckling the following day.

On admission for surgery, indirect ophthalmoscopy then revealed a giant retinal tear (GRT) from 10 to 2 o'clock with bullous retinal detachment (OS). Dr. Tseng changed the surgical plan to encircling scleral buckling with pars plana vitrectomy and gas tamponade. He said that during the surgery, "we observed a GRT with avulsion of the pars plana epithelium from the vitreous base, which was seen as an irregular ribbon within the vitreous cavity." To prevent the GRT from slipping, perfluorocarbon liquid was used intraoperatively.

Following the surgery, Dr. Tseng said that "the visual acuity in his left eye returned to 20/20 after cataract extraction six months later and the retina remained attached with break in bed one year after surgery."

In conclusion, the author pointed out how important preoperative assessment is – and that recognizing these conditions is crucial to providing the patient with optimal management and treatment.

Dramatic reenactment of blunt trauma causing retinal detachment.

IRIDEX

CYCLO G6® GLAUCOMA LASER SYSTEM

Non-incisional, repeatable, and for a wide range of glaucoma cases.
Over 100,000 probes and 1,100 systems shipped to more than 50 countries.
Used in 37 of the 39 best U.S. hospitals for ophthalmology[1]

MicroPulse P3™ Device

For earlier to advanced glaucoma therapies in **MicroPulse mode**.

G-Probe® Device

G-Probe Illuminate™ Device

For advanced glaucoma therapies in **continuous wave mode**.

Learn more at APVRS booth 26 or iridex.com/cyclog6

[1] As ranked in a recent report by U.S. News and World Report.

See More of Seoul

APVRS 2018 Delegate Tour Guide

by Brooke Herron

Welcome to Seoul: The capital AND largest city in South Korea. Here, modern skyscrapers and traditional palaces and temples find common-ground in this fashionable metropolis of pop-culture, history, shopping, dining and more.

With a sprawling metropolitan area, delegates at the Asia-Pacific Vitreo-retina Society (APVRS) will undoubtedly find numerous attractions, delights and sights to entertain in between the congress's impressive scientific program.

Quick Sights in Seoul

Busy delegates may not have too much time to explore – fortunately, the area surrounding the conference venue has multiple attractions nearby. Located in the popular Gangnam district, the event venue – Coex Convention and Exhibition Center – is not only well-recognized as events center, but a tourist attraction as well.

For pop culture aficionados, the Gangnam district owes some of its popularity to Korean Pop (K-pop) artist Psy and his song "Gangnam Style," which has garnered more than 2 billion online views worldwide. [And if you're not familiar with this song, or with K-pop in general, head over to YouTube.com for a quick education on Korean pop culture.]

Attendees needing a dose of retail therapy have easy access to Coex Starfield Mall, an underground shopping mecca with a large movie theater complex and numerous fine dining restaurants. Also located near Coex, is Bongeunsa Temple, constructed in 794, and home to 3,479 Buddhist scriptures. Admission is free, and the temple is open year-round. The Gangnam district is also home to several recreation areas including tourist destination Olympic Park, as well as Seonjeongneung Park, which is home to royal tombs.

Explore More of Seoul

Delegates with some free time will have ample options to explore in Seoul. For those seeking a bit of history, the Seoul capital area balances its modernity with an astounding five UNESCO World Heritage Sites: Changdeokgung Palace, Hwaseong Fortress, Jongmyo Shrine, Namhansanseong and the Royal Tombs of the Joseon Dynasty.

One of these sites, Changdeokgung (also known as Changdeok Palace), is the most preserved of the remaining royal palaces and is considered by some to be the most beautiful. It was initially completed in 1412, but subsequently burned down during a Japanese invasion in 1592. King Seonjo and King Gwanghaegun reconstructed the palace in 1609. Tourists must book a one-hour tour to look around, so check online or call ahead for more information.

Continuing on the palace theme, the Gyeongbokgung Palace (also known as Gyeongbok Palace) is said to be Seoul's most popular attraction. Constructed in 1395 by King Taejo, the founder of the Joseon Dynasty, it now houses 300 buildings including the National Folk Museum and National Palace Museum. Those in the know say to spend at least a half day inside the compound for the full experience. Free audio tours are available, check online for time slots.

Between these two palaces lies another must-see: Bukchon Hanok Village. Hanoks are traditional Korean homes

with tiled roofs and stone floors – and this neighborhood has 900, dating all the way back to the Joseon Dynasty. Traditional meets contemporary here as well – some of these hanoks have been transformed into tea houses, cafes, art galleries and museums, making it an ideal respite from a busy conference schedule.

Nature lovers can also rejoice in Seoul, as the city is surrounded by eight mountains and boasts numerous parks. Head to the city's guardian mountain Namsan and visit the N Seoul Tower, an iconic city landmark with an observation deck renown for the panoramic views of the cityscape below. There are two ways to reach the top: walking (which my Internet sources say isn't difficult) or cable car (which allows you to see more along the way). At the top of the 236.7-meter tower, there are two dining options: one upmarket, one casual.

A Dose of Retail and Culinary Therapy

For those seeking fun indoors (and out of the chilly weather!) head to Lotte World. Each year, more than 7.3 million people visit this major recreation complex, which includes: the world's largest indoor theme park; and outdoor amusement park; an artificial island, inside a lake, linked by monorail; shopping malls; a luxury hotel; a Korean folk museum; sports facilities; and movie theaters.

Markets and street food are also a big draw in Seoul. The Dongdaemun Market is Korea's largest retail shopping district, with more than 30,000 fashion shops and 50,000 manufacturers opened for 24-hours a day. Visitors will find all types of goods and services here, with a range varying from leather goods to fortune tellers and cuisine.

For a more traditional street market, check out Gwangjang Market – Seoul's largest food alley (or meokja golmok) with more than 200 food stalls. Foodies flock to this market to sample traditional Korean delights like mandu (Korean dumplings) and bibimbap and boribap (mixed rice and barley topped with a selection of veggies).

Certainly, between the congress and the dynamic city of Seoul, delegates will find numerous activities to fill their free time. The city's high-tech backdrop steeped in traditional roots creates an ideal backdrop for APVRS, one of Asia's most important ophthalmic conventions.

THIS IS DIGITAL

This is

NGENUITY®

DIGITALLY ASSISTED VITREORETINAL SURGERY

- High Magnification Performance [1]
- Extended Depth of Field[1]
- Integration with the CONSTELLATION® Vision System

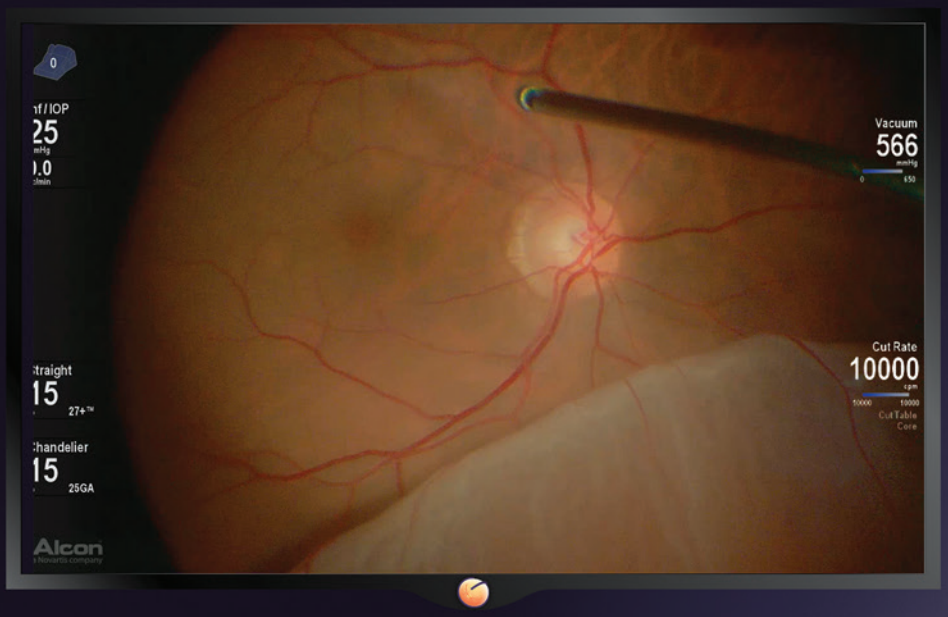

SEE IT BETTER. DO IT BETTER.

Reference: 1. Alcon Data on File. Yin L, Sarangapani R. Assessment of visual attributes for NGENUITY® 3D Visualization System 1.0 for digitally assisted vitreoretinal surgery. Alcon Modeling and Simulation. January 2016.

Alcon A Novartis Division