

Highlights

5 It's all about **retinal surgery!**

10 Experts discuss combating **retinal diseases**

13 How to go for **gold in macular intervention...**

Published by:



CEO & Publisher
Matt Young

Production & Circulation Manager
Hannah Nguyen

Chief Editor
Gloria D. Gamat

Associate Editor
Brooke Herron

Project Manager
Ruchi Mahajan Ranga

Publications & Digital Manager
Alex Young

Graphic Designers
Winson Chua
Edison Tan

Photographer
Dwayne Foong

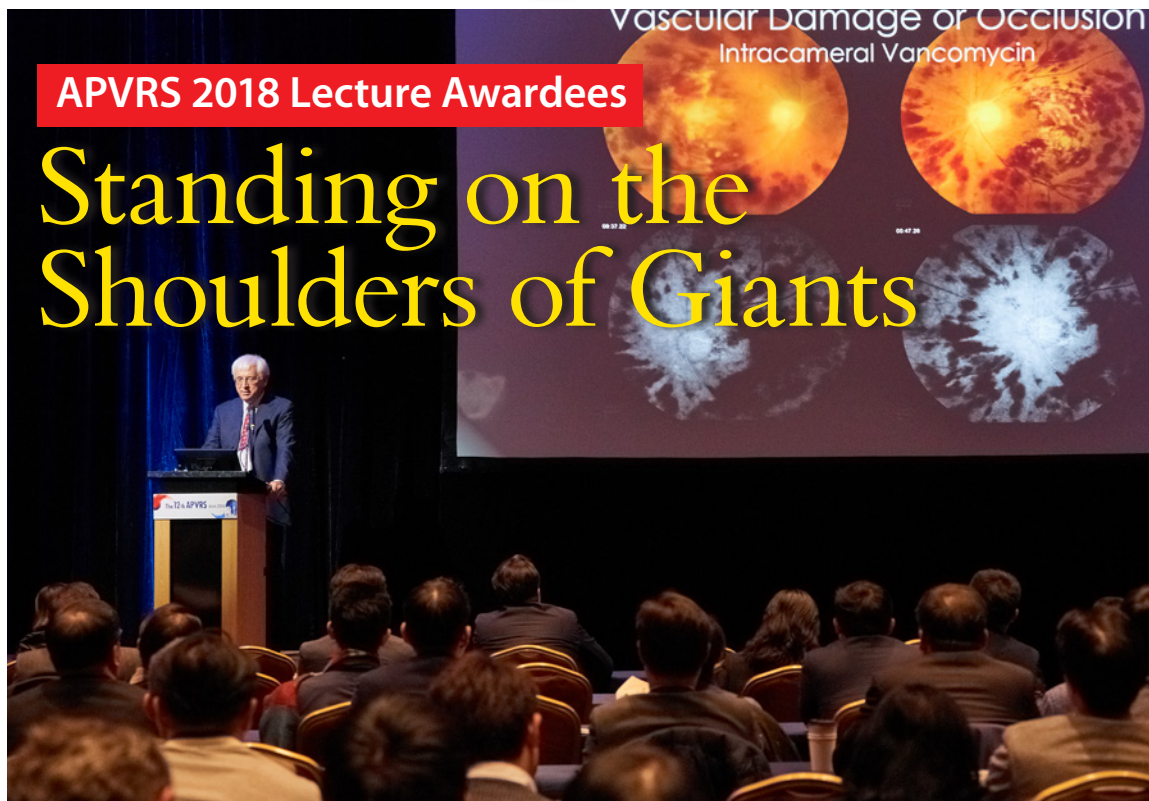Writers
Hazlin Hassan
Joanna Lee
John Butcher

Media MICE Pte. Ltd.
6001 Beach Road, #19-06
Golden Mile Tower,
Singapore 199589
Tel: +65 8186 7677
Fax: +65 6298 6316
Email: enquiry@mediamice.com
www.mediamice.com

www.piemagazine.org

APVRS 2018 Lecture Awardees

Standing on the Shoulders of Giants



by Joanna Lee

The Constable Lecture was established in 2016 in honor of Prof. Ian Constable, a world-renowned scientist in the vitreoretinal field and also a past president of APVRS. It recognizes individuals 45 years or younger for their outstanding contributions in advancing the understanding, diagnosis and treatment of vitreoretinal diseases. This year's recipient of the Constable Lecture award is Associate Professor Gemmy Cheung who currently is Head of the Retina Research Group, Singapore Eye Research Institute and Deputy Head of Medical Retina service, Singapore National Eye Centre (SNEC). She is also a clinician investigator and has experience in managing patients with age-related macular degeneration and diabetic retinopathy. And we're proud to say she is an Advisory Board member of PIE Magazine.


Dr. Cheung paid tribute to Prof. Constable, saying: "Prof. Constable was not only a world leader in ophthalmology, but a kind and patient teacher," she said. She also said Prof. Constable had "a long and strong bond with Singapore National Eye Centre" having trained several generations of surgeons at SNEC where she is based. Over the years, she has had the privilege of working with Prof. Constable over several

published studies. "It is indeed an honor to present this main lecture for the Constable Lecture," Dr. Cheung said.

With her research focus on Asian retinal diseases, Dr. Cheung presented her lecture titled "Polypoidal Choroidal Vasculopathy: A Focus on What We Don't Know". Her lecture covered key advances in the understanding of PCV over the past 10 years with updates on

Cont. on Page 7 >>

Photo of the Day



The shrimp were so succulent at the APVRS Party last night.







Bayer

For Healthcare Professionals Only

In treatment-naïve patients...

START STRONG STAY STRONG¹⁻⁴

EYLEA® is approved for patients with

-  Wet AMD(Wet Age-related Macular Degeneration)
-  DME(Diabetic Macular Edema)
-  RVO(Retinal Vein Occlusion)
-  mCNV(Myopic Choroidal Neovascularization)



 **EYLEA®**
(aflibercept solution for injection)

EYLEA® (Aflibercept) is an intravitreal anti-VEGF agent that has been bioengineered to have strong, broad, and long-lasting activity⁵⁻⁷

wet AMD (wet age-related macular degeneration), DME (diabetic macular edema), BRVO (branch retinal vein occlusion), mCNV (myopic choroidal neovascularization)

[Product Name] EYLEA® injection **[Composition]** 1 vial(0.278 ml) containing aflibercept 11.120 mg **[Indications, Dosage and Administration]** This drug is for intravitreal injection. It must only be administered by a qualified physician experienced in administering intravitreal injections. In general, adequate anesthesia and asepsis, including topical broad spectrum microbicide (e.g., povidone iodine), have to be ensured. Immediately following the intravitreal injection, patients should be monitored for elevation in intraocular pressure. Each vial should only be used for the treatment of a single eye. After injection any unused product must be discarded. The injection volume of this drug is 2mg (equivalent to 50 microliters). **1. Treatment of neovascular (wet) age-related macular degeneration** : This drug is initiated with one injection per month for three consecutive months, followed by one injection every 2 months. There is no requirement for monitoring between injections. Long term (after the first 12 months of treatment), it is recommended that patients continue to be treated with this drug every 2 months. **2. Treatment of visual impairment due to macular edema secondary to retinal vein occlusion (branch RVO or central RVO)** : After the initial injection, treatment is given monthly. The interval between two doses should not be shorter than one month. If visual and anatomic outcomes indicate that the patient is not benefiting from continued treatment, Eylea should be discontinued. If there is no improvement over the course of the first three injections in case of CRVO patient, continued treatment is not recommended. Monthly treatment continues until maximum visual acuity is achieved and/or there are no signs of disease activity. Three or more consecutive, monthly injections may be needed. The monitoring and treatment schedule should be determined by the treating physician based on the individual patient's response. **3. Treatment of visual impairment due to diabetic macular edema** : The recommended dose for EYLEA is 2 mg administered by intravitreal injection monthly for the first 5 consecutive doses, followed by one injection every 2 months. **4. Treatment of visual impairment due to myopic choroidal neovascularization** : After initial injection, additional doses should be administered only if visual and anatomic outcomes indicate that the disease persists. The interval between two doses should not be shorter than one month. If visual and anatomic outcomes indicate that the patient is not benefiting from continued treatment, Eylea should be discontinued. The monitoring schedule should be determined by the treating physician. For further information about Dosage and Administration, please see the full Eylea® product information **[Contraindication]** **1. Contraindications** : 1) Ocular or periocular infection 2) Active severe intraocular inflammation 3) Known hypersensitivity to any ingredient of this drug **2. Special precautions** : 1) Intravitreal injection-related reactions: Intravitreal injections, including those with Eylea, have been associated with endophthalmitis, intraocular inflammation, rhegmatogenous retinal detachment, retinal tear and iatrogenic traumatic cataract. Increases in intraocular pressure have been seen within 60 minutes of an intravitreal injection, including with this drug. 2) Arterial thromboembolic events (ATE) **3. Adverse Reactions** : Very common (≥1/10): Conjunctival hemorrhage, Eye pain, Common (≥1/100 ~ <1/10): Retinal pigment epithelial tear, Detachment of the retinal pigment epithelium, Cataract, Cataract cortical, Cataract nuclear, Cataract subcapsular, Corneal erosion, Corneal abrasion, Intraocular pressure increased, Vision blurred, Vitreous floaters, Vitreous detachment, Injection site pain, Foreign body sensation in eyes, Lacrimation increased, Eyelid edema, Injection site hemorrhage, Punctate keratitis, Conjunctival hyperemia, Ocular hyperemia **[Ethical Drug]** **[Imported and Marketed by]** Bayer Korea Ltd. Korea **[The latest revision date]** 02-May-17 For further detailed information, please refer to the full Eylea® local product information or Bayer Korea website, <http://www.bayer.co.kr/>

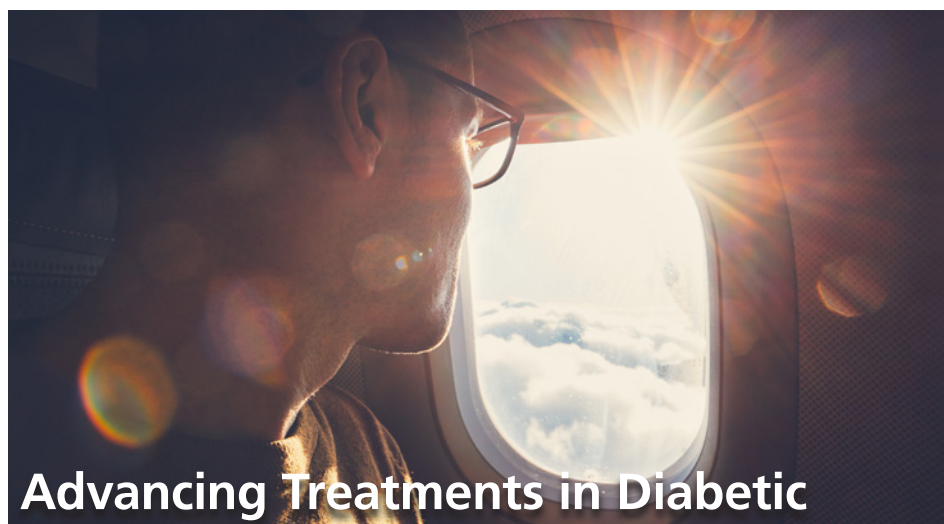


Bayer Korea Ltd.

SamSung Baramae Omni Tower, 23 Baramae-ro 5-gil, Dongjak-gu, Seoul 07071, Korea
Tel +82 2 829 6600 | <http://www.bayer.co.kr/>
COPYRIGHT©BAYER KOREA Limited | PP-EYL-KR-0105-1

Reference:

1. Heier JS et al. *Ophthalmology* 2012;119(12):2537-2548
2. Korobelnik JF et al. *Ophthalmology* 2014;121(11):2247-54
3. Kaiser PK et al. *Ophthalmology Retina* 2017;1:304-313
4. Heier JS et al. *Ophthalmology* 2016;123:2376-2385
5. Papadopoulos N, et al. *Angiogenesis*. 2012;15:171-185
6. Stewart MW. *Br J Ophthalmol*. 2012;96:1157-1158
7. Fauser S et al. *Am J Ophthalmol*. 2014 Sep;158(3):532-6



Advancing Treatments in Diabetic

Macular Edema

by Joanna Lee

One of the most feared complications for patients with diabetes is the loss of sight. The impact is deep and possibly life changing. However, the inversed situation is equally significant when diabetic patients start to gain back lost vision. South Korean Asan Medical Centre's Professor Dr. Young Hee Yoon's opening notes graciously introduced participants to the topic of "Advances in Diabetic Macular Edema (DME) Treatment" where she drew participants to how five-letter gains in the best corrected visual acuity (BVCA) would become "clinically meaningful to patients". This was derived from the findings and results of the landmark VIVID and VISTA studies of diabetic macular edema (DME). Dr. Yoon also said the area under the curve analysis (AUC) which provides key information about day-to-day visual experiences of patients that cannot be gained from examining individual time points, she pointed out the observation that treating DME patients with aflibercept early may minimize the duration one endures with poor vision and provide meaningful final vision gains.

Dr. Gemmy Cheung, senior consultant ophthalmologist at Singapore National Eye Centre (SNEC) and a clinician investigator at the Singapore Eye Research Institute (SERI) presented on clinical updates in the management of DME where she brought the audience through the developments in the understanding of the roles which vascular endothelial growth factor (VEGF) and placental growth factor (PIGF) play in

contributing towards the development of retinal vascular leakage and edema in diabetic eye disease, explaining how inflammation, vascular permeability and neovascularization happens. It has been discovered that VEGF and PIGF were found to be significantly higher in the vitreous of patients with active proliferative diabetic retinopathy (PDR) than in the vitreous of those with quiescent PDR.

Dr. Cheung also demonstrated how aflibercept was specifically designed for high-affinity binding to VEGF and PIGF where aflibercept incorporates domains from two VEGF receptors for tight binding on both sides of VEGF and PIGF, preventing interactions with other molecules. Its efficacy has been supported by numerous clinical trials such as the three-year VIVID and VISTA studies as well as the two-year DRCR.net Protocol T2 study. These studies have shown that aflibercept, when used during intensive treatment of visual impairment caused by DME, gives rise to an accelerated and increasing visual improvement which is maintained in the long term, she said. This is especially seen with the visual acuity gains achieved with early aflibercept treatment within Year 1.


In the study, patients across both

studies gained more than 9 letters (about two lines of vision) on average after 5-monthly loading doses. In some patients, aflibercept has shown a regressing effect on the symptoms of diabetic retinopathy. On the other hand, the study also showed how the delay of anti-VEGF treatment may lead to irreversible vision loss. Dr. Cheung shared about the APOLLON study as an example of real-world evidence of aflibercept's effectiveness with patients achieving good vision gains at 6 months, a result consistent with what has been reported in clinical trials.

A specialist in retinal diseases, Professor Neil Bressler from the Wilmer Eye Institute at Johns Hopkins University School of Medicine and Hospital, USA, unraveled some practical insights looking at how one can choose an anti-VEGF treatment regimen for DME, sharing pertinent clinical insights from the DRCR Network, in particular from the Protocol T study. Based on the comparisons of mean changes in OCT CST and mean change in visual acuity for patients on aflibercept, bevacizumab and ranibizumab, it was seen that those on aflibercept recorded the most positive VA improvement. On that, Dr. Bressler also reiterated that OCT outcomes cannot be equated with visual acuity outcomes. However, it was also observed that aflibercept was not as effective as ranibizumab at the two-year point to which Dr. Bressler said it's "because aflibercept group outcomes are superior to ranibizumab's after over two years when the baseline VA 20/50 or worse. He also expounded on the reasons for starting with 6 injections while exploring the question if DRCR Network's treatment regimen for DME lead to a decrease in number of injections over 5 years. He also shared that any trace of edema left behind, as opposed to the current perceptions, is not harmful and that laser can and should be considered alongside anti-VEGF treatment. ☺



Dr. Gemmy Cheung



Dr. Young Hee Yoon



Prof. Neil Bressler

Much to Do About *Melanoma*

by John Butcher

Major advances have been made in the treatment of melanoma, but there remains “much to do,” according to Dr. William Mieler of the University of Illinois in Chicago, USA.

During an early morning session on day two of the 12th Asia-Pacific Vitreo-retina Society Congress (APVRS 2018) in Seoul, Korea, Dr. Mieler ran through the treatments, associated complications and factors that might influence taking action.

Thirty years ago the rate of misdiagnoses ranged from between 20 percent and 30 percent, he said, but with the advent of indirect ophthalmoscopy and echography, that has fallen to less than one percent. A fine needle aspiration biopsy can be performed when there is uncertainty of the diagnosis, he added.

As well as improved diagnosis there are also numerous treatment options today, according to Dr. Mieler, although the selection and timing of therapy remains “somewhat controversial.”

Therapeutic options include observation, enucleation, photocoagulation therapy, brachytherapy, charged particle radiation proton beam treatment, external beam radiation therapy, pre-enucleation radiation therapy, other means of radiation delivery (such as a cyberknife, gamma knife and stereotactic radiosurgery), tumor resection and a combination of treatments.

Factors that influence the decision on what therapy to use include the size, location and activity of the tumor, the status of the fellow eye, the age of the patient and their general physical and psychological health, he said.

A small tumor would be around two to three millimetres in height with a four to six millimeter base, he added, while one considered extra large would be more than eight millimetres in height with a base in excess of 16 millimeters.

An active tumor can be identified as one breaking through the Bruch’s membrane, as well as by subretinal fluid, ill-defined orange pigmentation and relatively sparse drusen, he said.

Dr. Mieler identified multiple risk factors for tumor growth, including a thickness of more than two millimeters,



the presence of subretinal fluid, orange pigment and margins touching the optic disc. With no risk factors there is a less than three percent chance of growth within five years, he said, but with two or more risk factors present, the likelihood of growth rises to more than 50 percent within five years.

Ablative photocoagulation had been a common treatment for posterior segment tumors with a thickness of less than 3.5 millimeters, Dr. Mieler told the audience, but was infrequently used today due to extensive morbidity.

When laser is employed, it is “now generally as an adjunct” to plaque radiotherapy, he said, although even in this setting it is more common to employ transpupillary thermotherapy.

Brachytherapy is the “mainstay” of current therapy, he said. Its advantages are that it preserves at least some vision, produces no apparent increased mortality in retrospective case matched studies and is comparable to enucleation surgery for medium-sized tumors according to the Collaborative Ocular Melanoma Study.

On occasion brachytherapy is combined with transpupillary thermotherapy, photocoagulation, and bevacizumab, he added.

Despite its popularity, brachytherapy is not without its own complications, said Dr. Mieler, which includes tumor

unresponsiveness in five to ten percent of cases, optic neuropathy, cataract, neovascular glaucoma, vitreous hemorrhage, and scleral necrosis. It can also lead to radiation-induced optic neuropathy, retinopathy or maculopathy in 35 percent to 40 percent of cases, he added.

Charged particle radiation, using proton beam or helium ion irradiation is another option, Dr. Mieler continued. Its advantages include being highly focused, with minimal scatter, although it does come with complications including lack of availability, placement of marker rings that may require extensive ocular manipulation and similar complications to brachytherapy with potentially higher incidence of anterior segment complications.

Some experimental alternative treatments include combining brachytherapy with intravitreal bevacizumab in an attempt to limit the post-treatment complications of radiation, as well as combining brachytherapy with pars plana vitrectomy (PPV) and the use of silicone oil, which blocks radiation by around 40 percent.

External beam radiation has been shown to potentially slow tumor growth, he said, although concerns have been raised about the ability of the eye to tolerate such a high dose of radiation and it is rarely used today.

Melanoma is relatively easily diagnosed and there are many treatments, concluded Dr. Mieler, the most popular of which today is brachytherapy. If the tumor metastasizes outside the eye, the prognosis is poor though, he added.

“Work is ongoing, but there is much to do,” he said. ☺



All About Retinal Surgery

by Hazlin Hassan

Experts shared their experiences with retinal surgeries at the 12th Asia-Pacific Vitreo-retina Society Congress (APVRS 2018) in Seoul, Korea, yesterday.

Dr. Ashish Ahuja, from Bharti Eye Hospital and Foundation, India, presented his paper on "Posterior segment complications following valve surgery in vitrectomized eyes."

He discussed vision threatening posterior segment complications following Ahmed Glaucoma Valve (AGV) surgery in two eyes that have had previous vitreous surgery, where both eyes had intractable glaucoma.

He concluded that AGV surgery in vitrectomized eyes can lead to severe vision threatening complications, such as non-resolving sub-ILM (internal limiting membrane) bleed, but added that the cases in his study were managed successfully. The absence of vitreous support in such eyes could be the possible cause of sudden decompression and severe hypoton leading to such posterior segment complications, he said.

Dr. Manabjyoti Barman, of Vitreo Retina and Ocular Oncology Services, Sri Sankardeva Nethralaya, Guwahati (Assam) India, shared insights on "Conventional internal limiting membrane (ILM) peeling versus Inverted ILM flap technique for macular hole surgery."

The aim of the study was to compare the single-surgery closure rate and visual outcome of inverted ILM flap technique against the conventional ILM peeling in cases of large macular holes in clinical practice.

He pointed out that surgical management of large macular holes is challenging.

"In our series, we could not find significant differences in terms of visual outcomes between the two study groups. However, stable visual recovery was noted with the ILM flap technique," he said.

In conclusion, he said that the inverted flap technique is a useful alternative in large macular hole surgery, and it has an edge in terms of marginally high closure rate with faster visual recovery.



Dr. Ashish Ahuja



Dr. Manabjyoti Barman



Dr. Haiyan Xu



Dr. Jane Foo

Haiyan Xu, M.D., from the Department of Ophthalmology, Peking Union Medical College Hospital, Chinese Academy of Medical Sciences discussed "Efficacy of Intravitreal Injection of Conbercept in Diabetic Macular Edema (DME)."

DME is becoming more prevalent, and has become the leading cause of diabetic retinopathy blindness. It is usually managed with focal or grid laser and anti-VEGF drugs. She presented on a randomized double-masked clinical trial to evaluate the functional and structural effects of Conbercept in patients with DME.

Conbercept, which is currently approved for use only in China, is given as an ophthalmic injection and is a fusion protein that binds to all isoforms. She concluded that the IV-Conbercept treatment experienced

more best corrected visual acuity (BCVA) improvement and central retinal thickness (CRT) reduction than those who underwent grid or focal laser treatment. Thus, it looks to be a promising option for the treatment of DME.

Dr. Jane Foo, of Malaysia, talked on "Anatomical and Functional Outcomes Following Vitrectomy For Primary Rhegmatogenous Retinal Detachment (RRD) with Proliferative Vitreoretinopathy (PVR) Grade C."

The mainstay of treatment of PVR is surgery, she said, adding that these are technically difficult surgeries with techniques which include combined buckles with vitrectomy, retinectomy, and long acting tamponade.

Anatomical success after surgery is 60 to 80 per cent. However functional success (ambulatory vision of 5/200 or better) is only 40 to 80 per cent of patients. She pointed out that studies on the optimal surgical technique have been conflicting.

There is higher reattachment rate in combined vitrectomy buckle using primary pars plana vitrectomy (PPV) and scleral buckle (SB) compared to (PPV) alone, while it was not significant in another study. Other studies showed better anatomical and visual outcome with PPV and retinectomy without buckle.

Epiretinal membrane occurs in 10 to 20 per cent of eyes after surgery for PVR, she noted.

To sum up the results of the study, she said that there was no difference between retinectomy or combined vitrectomy buckle. Both techniques have their advantages and indications, she said.

All reattached cases had second surgery which involved retinectomy, demonstrating the effectiveness of retinectomy in relieving persistent traction with retinal shortening. Mean BCVA improved postoperatively.

"The success seen in this study demonstrates the importance of surgical intervention, which could potentially improve the anatomical and visual outcome." 🧐



Asia-Pacific Vitreo-retina Society (APVRS) Congress 2019

Shanghai International Convention Center, China

November 22-24, 2019



HOSTS:



Asia-Pacific Vitreo-retina Society



Chinese Vitreo-retina Society



APVRS.ORG



APVRS



2019.apvrs.org

>> Cont. from Page 1

PCV. While acknowledging the advances in the field, she posed several questions which could be guideposts for further ventures in the brave new world of PCV research. With the standardization of ICGA-based diagnostic criteria, is it time to incorporate other imaging modalities into the diagnostic criteria? She also pondered on the role of choroidal changes in PCV, what determines choroidal thickness, and how to reconcile the pachychoroid concept with AMD. Touching on the positive randomized controlled trial (RCT) results from combination therapy as well as monotherapy, Dr. Cheung spoke on the choice of initial therapy and also what would be the long term outcome and influencing factors of these good visual outcomes of up to 2 years in RCTs. Moving forward, international collaborations are in store as Dr. Cheung revealed she would be leading a follow-up study to the EVEREST/PLANET study, a wide scale investigation involving 35 sites from Japan, Korea, Taiwan, Singapore, Malaysia, Hong Kong, Thailand, and Australia.

Following the invigorating presentation, Prof. William Mieler, Cless Family Professor of Ophthalmology and vice chairman of education in the Department of Ophthalmology & Visual Sciences at the University of Illinois at Chicago (UIC) was the recipient of the APVRS International Lecture award. The award was established in 2017 and it recognizes individuals from outside the Asia-Pacific region for outstanding contributions in advancing the understanding, diagnosis and treatment of vitreoretinal diseases.



“Prof. Constable was not only a world leader in ophthalmology but a kind and patient teacher.”

- Dr. Gemmy Cheung


His lecture was on “The Impact of Systemic Medications on Retinal Toxicity” with a focus on specific medications, the classifications and impact of effects on the retina, as well as the mechanisms of toxicity when known. He pointed to various drugs that has side effects which lead to vascular damage or occlusion, macular and retinal edema. Other examples were drug-induced myopia which included responses to sulfur derivative medications and topiramate, a drug shown to cause angle-closure glaucoma. Dr. Mieler also shared how crystalline depositions occur when canthaxanthine, tamoxifen, methoxyflurane, nitrofurantoin and talc are used. The use of rifabutin and cidofovir is related to uveitis. There are also chemotherapeutic agents that doctors should be aware of. He brought up cases involving the use of hydroxychloroquine and showed its effect on the retina.

Screening recommendations were given for general screening, SD-OCT, fundus autofluorescence (FAF), multi-focal electroretinogram (mf-ERG), and

microperimetry with a caution on types of screenings which are not recommended (amsler grid, fluorescein angiography, color vision testing, and full-field ERF and or EOG). Dr. Mieler also expounded on the use of thioridazine and dideoxyinosine (DDI), gentamicin and vancomycin and paclitaxel towards the end. “If you see changes, stop the medication,” he reminded at several points in the lecture. He also said as a parting point, “It is important to recognize the usual patterns of toxicity and be alert for possible new associations in the future.”

The next lecture was the Hyung-Woo Kwak International Lecture award which was presented to Dr. Judy E. Kim who is professor of ophthalmology at the Medical College of Wisconsin. She said a leader was one who guided on a way in advancement, directs on a course and serves as a channel. “We stand on the shoulders of giants. And Dr. Hyung Woo Kwak was a giant, he was a leader and he was a visionary and I am truly honored to receive this award that is honoring his name. And I miss him very much,” Dr. Kim said.

She spoke on “Transforming Ophthalmology Through Teleophthalmology”, a topic which addresses the next generation of ophthalmologists, putting forth the field of teleophthalmology as the way to go for eye care in the future due to the overwhelming number of cases projected to grow globally. With this method that could bring access to large populations, adaptable to vastly different environments, increase early screening and reduce health care costs, besides spanning diverse cultures, she suggested this as a paradigm shift in the delivery



“It is important to recognize the usual patterns of toxicity and be alert for possible new associations in the future.”

- Dr. William Mieler



“We stand on the shoulders of giants. And Dr. Hyung Woo Kwak was a giant, he was a leader and he was a visionary and I am truly honored to receive this award.”

- Dr. Judy Kim

of health care “by the community, for the community, and in the community – it’s feasible in the community by the laypeople,” she said, adding it could also be done individually through home devices and like a home testing and reporting device, or home OCT.

The development of new imaging modalities and the incorporation of artificial intelligence is also a trend that can’t be ignored. “It may be time to realize it’s not man against machine, but man and machine together that can finally create the biggest improvements in human health,” she said.

Dr. Kim said the lecture award is very meaningful to her as she had left Korea for the United States when she was nine years old. “I will continue to work hard to be a bridge, to be a liaison between east and west,” she said before recording her gratitude to those who have contributed to her success along the way.

Finally, the Hyung Woo Kwak Asia Pacific Lecture award was presented by this year’s recipient, Prof. Dennis Lam, current president of the Asia-Pacific Vitreo-retina Society (APVRS), immediate past president of the Asia-Pacific Academy of Ophthalmology (APAO) and one of the key leaders in ophthalmology in the Asia-Pacific Region. He chose to speak on “Grooming the Future Leaders in Ophthalmology in the Asia-Pacific

Region”. Dr. Lam gave an inspiring take on leadership. He spoke using the acronym VIPS to demonstrate what leadership is about. He said “Our future depends on how good our successors are. We need visionary leaders,” he said, pointing to the “V” of being a leader. “The “I” is for inspiration. So, if you open the refrigerator, you will see the light inside,” he said, bringing his touch of humour to his address. He followed up with wise words the importance of Partnership, the “P” in VIPS and how important it is to make the journey more pleasant (and shorter) by collaborating with others. Dr. Lam also stressed on how vital it is to manage our priorities and to prevent stress.

The lectures ended with Dr. Jay Chhablani presenting the results of the Asia Pacific Technology and Trend Survey 2018 on behalf of APVRS.

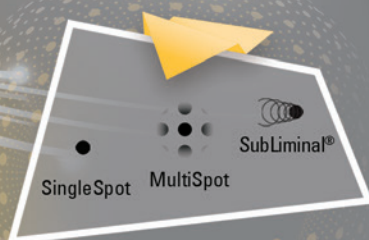
Meanwhile, see you at APVRS 2019 in Shanghai! 🌐



“Our future depends on how good our successors are. We need visionary leaders.”

- Dr. Dennis Lam

eas ret®



577NM LASER SUBLIMINAL® MODE

VISIT US AT
APVRS
Booth #8-10

Versatile:

- Pure yellow 577 nm wavelength for central and peripheral treatments

Safe and efficient software guided procedures:

- Tissue sparing SubLiminal® mode for **DME** and **CSCR** treatments
- MultiSpot mode for fast and comfortable **PRP** treatments
- SingleSpot mode for classic laser treatments

Innovative reliable technology:

- Advanced fiber laser technology cavity featuring a **5-year warranty**

Learn more about clinical aspects on
www.subliminal-laser-therapy.com

Headquarters:
Tel: +33 (0)4 73 745 745
info@quantel-medical.fr

Quantel
medical
www.quantel-medical.com

Tracing the **What** and **Whys** of Eye Traumas



by Joanna Lee

It has been reported that 30 to 40% of monocular blindness is caused by ocular trauma.¹ Thus, more ought to be done for the treatment and prevention of such incidences. The epidemiology differs in different parts of the world. In this session of Rapid Fire Ocular Oncology & Eye Trauma at the 12th Asia-Pacific Vitreo-retinal Society congress (APVRS 2018) in Seoul, Korea, the audience got a sampling of interesting studies and updates from around Asia which seemed to provide a view into an area where many are still trying to gain an understanding of the epidemiology, causes and treatment modalities available for eye traumas.

Children are vulnerable to eye injuries. Moreover, due to the lack of information related to intraocular foreign bodies-related endophthalmitis within the pediatric population, Dr. Yang Yao from Zhongshan Ophthalmic Center at Sun Yat-sen University (Guangzhou, China) and her team decided to investigate the "Epidemiology and Clinical Features of Endophthalmitis with Intraocular Foreign Bodies in Children of Southern China: a 13-year Review". The retrospective study of 484 patients aged 0-17 years found that males accounted for the majority of patients. What was interesting was the analysis showed various risk factors where metallic foreign body, iris or choroid prolapse and hematophthalmia were significant protective factors while zone II wound and traumatic cataract were

significant risk factors in the development of endophthalmitis.

The issue of retinal hemorrhage after blood transfusion in patients with chronic or severe anemia was addressed by Dr. Anuj Soni and Dr. Pooja Lal from India. While physicians are familiar with retinal hemorrhage in anemia, there are very few cases of retinal hemorrhages in patients who are undergoing blood transfusion. After looking at two case studies of patients with sudden vision loss or vision dimness after blood transfusions, they concluded that an etiological relationship of transfusions to retinal hemorrhages cannot be established at this point. However, retinal hemorrhages following transfusions have occurred only in conditions predisposing to hemorrhages.

A series of cases of central retinal artery occlusion was reported by Dr. Ritu Shah from Aditya Jyot Eye Hospital in Mumbai, India, in his presentation "Know Your Enemy: The Many Faces of CRAO". Here, the various treatment modalities for this disease akin to a cerebral stroke were discussed such as IOP lowering, ocular massage, systemic control and vitrectomy.

From Nepal, Dr. Sanjita Sharma from the Tilganga Institute of Ophthalmology shared her study's findings in her presentation, "Clinical Characteristics, Visual Acuity, and Globe Survival in Posterior Segment Intraocular Foreign Body. They found endophthalmitis, retinal detachment, and duration of intervention

from the time of injury to be risk factors for the visual prognosis of patients with posterior segment IOFB and who have also undergone pars planar vitrectomy (PPV) at their institute.

In Korea, Dr. Baek-Lok Oh from Seoul National University Hospital in South Korea, presented a study which observed the nationwide incidence of post-operative endophthalmitis following cataract surgery.

It was found that postoperative endophthalmitis has decreased by 9.8% per year from 0.103% in 2002-2005 to 0.045% in 2010-2013 but for diabetic patients, post-cataract surgery endophthalmitis did not increase during the same time frame.

How about if the foreign body is alive? Dr. Irma Suwandi Sadikin from Department of Ophthalmology, Hadji Boejasin Public Hospital, in Pelaihari, South Borneo, Indonesia, reported a rare case of "Eye Worm Swimming Live in Anterior Chamber: How to Remove Live Nematode without Damaging Eye Structure? First Report from South Borneo, Indonesia. A male student had presented with complaints of irritation and photophobia, showing no abnormality in his blood count and everything else, the ophthalmologic exam showed a foreign body in his right eye. It was wriggling. An anesthesia with subcorneal injection was used with a 2.75 mm incision. Then, a mixture of 1:1 lidocaine and NaCl 0.9% were injected. While the worm was less active, its body was removed from the eye by utrula forceps. Later, it was identified as a resembling a filarial worm. They referred to a previous study to ascertain how a worm could travel to the eye. However, most importantly, it was a demonstration of the use of lidocaine as a chemo-paralysis agent which has an anesthetic effect on the eye, useful in reducing eye damage.

The session was chaired by Drs. Rajiv Raman and Heeseong Yoon. ☺

¹ Aghadoost D. Ocular Trauma: An Overview. *Arch Trauma Res.* 2014. 3(2): e21639.

Combating Retinal Diseases

by Hazlin Hassan

Dr. Sungjae Yang



Dr. Mark Gillies



Dr. Chaitra Jayadev

Ophthalmologists at the 12th Asia-Pacific Vitreo-retina Society Congress (APVRS 2018) in Seoul, Korea, shared on how to treat retinal diseases yesterday during the medical retina rapid fire session.

Dr. Mark Gillies, from the Save Sight Institute, University of Sydney, Australia, shared the findings of the RIVAL study comparing ranibizumab vs aflibercept for nAMD using a treat and extend protocol.

The study sought to investigate whether there is a difference in development of macular atrophy between ranibizumab and aflibercept when using a treat and extend regimen to treat the study eye of patients with neovascular age-related macular degeneration (nAMD), with respect to the growth in the area of macular atrophy over 24 months. It also sought to investigate comparative efficacy outcomes of the treat and extend regimen between ranibizumab and aflibercept for nAMD, in terms of number of injections.

"The study found no significant difference between ranibizumab and aflibercept in the development of macular atrophy in nAMD patients treated over 24 months," he concluded. The two achieved similar number of injections, visual acuity and retinal thickness improvements over 24 months using a treat and extend regimen, with comparable safety results.

Dr. Chaitra Jayadev of the Vitreoretina Department of Narayana Nethralaya Eye Institute, Bangalore, India, spoke about the need for more affordable treatment alternatives in "Efficacy of an indigenous intravitreal ranimizumab biosimilar for

macular edema management."

She pointed out that 5 million people died from diabetes in 2015 and a cheaper alternative to anti-VEGF therapy was needed as the cost can be prohibitive for some patients in India.

"In India, for an average of 5-7 injections a year with doctor visits, scans and travel, the cost can be quite expensive especially for a patient who is not medically insured which is the norm for most patients in India, so we need an alternative," she said.

In this case, biosimilars, or biopharmaceutical drugs designed to have active properties similar to one that has previously been licensed, may be an option, she said.

One such drug is Razumab, a biosimilar of ranibizumab.

It has completed preclinical studies in 2012, and started Phase II Clinical trial in October 2013, she said. However, she noted it was important that biosimilars should prove to be comparable to the innovator biologic to establish biosimilarity with respect to pharmacokinetics, pharmacodynamics, immunogenicity, safety and efficacy. She cited a study in which Razumab was found to have effectively improved visual acuity and disease outcomes in patients with retinal vein occlusion in a real-world setting with no new safety concerns. "Razumab is a viable and affordable option or macular edema treatment, with good clinical outcomes and compliance," she said.

Sungjae Yang, M.D., Ph.D., of J's Retina Clinic, Gangneung, Korea, shared on

"Prognostic factors for the response to intravitreal bevacizumab treatment in central serous chorioretinopathy (CSC) patients."

CSC is characterized by localized serous neurosensory retinal detachment. The pathogenesis is associated with hyperpermeability of choroid and retinal pigment epithelial dysfunction. While there are no gold standard treatments for CSC, the prognosis is relatively good. Treatments include focal laser photocoagulation, photodynamic therapy (PDT), corticosteroid antagonists and acetazolamide.

Dr. Yang presented details of a study which evaluated prognostic factors associated with a good response to intravitreal bevacizumab for CSC patients. A total of 94 patients were given intravitreal bevacizumab injection as a first line treatment from July 2013 to April 2018. The study concluded that these prognostic factors were associated with a good response: relatively acute onset, better initial visual acuity, and thicker choroid thickness.

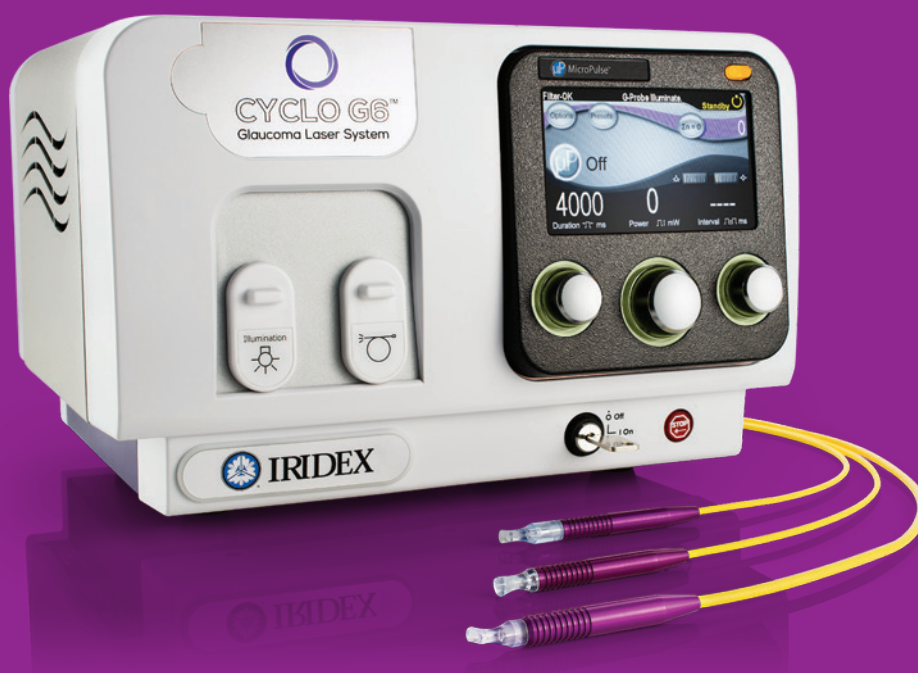Dr. Adrian Fung, Vitreoretinal Fellowship Director of Westmead Hospital, Sydney, Australia, talked about a real-life 24-month study on dexamethasone implants for diabetic macular edema (DME). It sought to evaluate the efficacy and safety of intravitreal dexamethasone implants in both treatment-naïve and refractory DME patients. Results showed functional and anatomical improvement in all eyes, and noted that earlier treatment may be beneficial. ●



IRIDEX

CYCLO G6[®] GLAUCOMA LASER SYSTEM

Non-incisional, repeatable, and for a wide range of glaucoma cases.
Over 100,000 probes and 1,100 systems shipped to more than 50 countries.
Used in 37 of the 39 best U.S. hospitals for ophthalmology¹



MicroPulse P3[™] Device

For earlier to advanced
glaucoma therapies in
MicroPulse mode.



G-Probe[™] Device



G-Probe Illuminate[™] Device

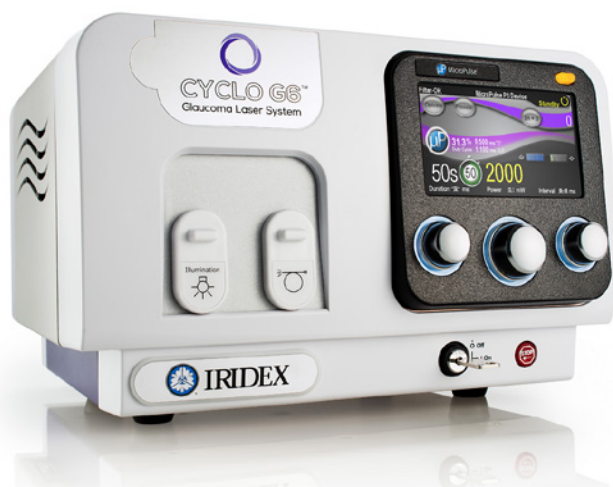For advanced glaucoma therapies in
continuous wave mode.

Learn more at APVRS booth 26 or iridex.com/cyclog6

¹ As ranked in a recent report by U.S. News and World Report.

© 2018 IRIDEX. All rights reserved. IRIDEX, the IRIDEX logo, Cyclo G6, MicroPulse, and G-Probe are trademarks or registered trademarks of IRIDEX. AD0190.C 11.2018

Cyclo G6 Laser System Shows Promise for Glaucoma Patients



As the most prevalent optic neuropathy, the second most common reason for vision loss, and the most frequent cause of avoidable vision loss globally¹, it's estimated that glaucoma will affect 76 million people by 2020.² With such a high disease burden, safe and effective treatment is critical to saving the sight of millions.

Current therapy focuses on lowering intraocular pressure through topical anti-glaucoma medications – however, patient compliance remains an obstacle to continued and successful disease management and treatment. And though there have been advances in these medications – like combination drops and new chemicals and delivery methods – there is evidence that long-term use of topical drugs can increase the risk of failure of later incisional glaucoma surgery.³

New laser system targets glaucoma

Now, patients and physicians have an alternative to topical drops with the Cyclo G6® laser system from Iridex Corp. (CA, USA). The first in its class, the laser system is specifically designed to treat patients diagnosed with a range of glaucoma disease states. The Cyclo G6 uses MicroPulse “tissue-sparing” technology, which results in a much safer procedure, while retaining the efficacy of a traditional, continuous wave TSCPC procedure.

MicroPulse is a very directed laser

modality that chops a continuous wave laser beam into a series of tiny “packets,” which are repeatedly delivered over a longer period (a 30% duty cycle means the laser is on 30% of the time and off 70%). This creates just enough laser energy to be absorbed in the cells of the pigmented ciliary epithelium to shrink them, while preventing thermal build-up and collateral damage to surrounding tissue.

Recent studies have caused a paradigm shift in the understanding and use of laser therapies. In fact, research in retinal photocoagulation has demonstrated that rather than decreasing the production of angiogenic factors (from the destruction of retinal cells), selective destruction of photoreceptors with lasers (while sparing the inner retina) begins a healing cascade that increases the availability of oxygen, while reducing the angiogenic and permeability factors.⁴ And the latest research shows that MicroPulse TSCPC causes ciliary body remodeling, which not only reduces aqueous production, it also increases outflow motion.⁵

The laser advantage


The MicroPulse TSCPC with the Cyclo G6 system is advantageous for a wide variety of glaucoma patients including those with early to moderate disease, those who may be poor surgical candidates, and those who have high risk ocular comorbidities.

The system is supported by a growing body of clinical evidence and extensive validation in the field for the treatment of glaucoma. According to Dr. Shan Lin, a glaucoma specialist at the Glaucoma Center of San Francisco (CA, USA), the Cyclo G6 MicroPulse has had a tremendous impact on his practice: “It is the number one glaucoma surgery I do. It has become my go-to procedure

because of the safety profile. It is what I turn to after patients are refractory to medications.”

In addition to its benign safety profile, MicroPulse TSCPC can be titrated to the severity of disease by repeating the procedure as necessary. Clinical data shows that patients may need between one and three procedures to show a reduction in intraocular pressure of approximately 30%, as well as a decrease in the number of medications needed.

The laser system is sold with three different disposable probes: the MicroPulse P3™ probe for use with a broad range of glaucoma patients; the G-Probe® device for later-stage patients; and the G-Probe Illuminate™ device that combines transillumination and laser fiber for targeted transscleral cyclophotocoagulation.

The Cyclo G6 has been approved for use by more than 50 countries, including by the South Korean Ministry of Food and Drug Safety, and more than 100,000 patients have been treated with the system worldwide. In addition, it's being used in 37 of the 39 “Best Hospitals for Ophthalmology” as ranked by the U.S News and World Report. In South Korea, the Cyclo G6 Laser is distributed by Kisan Tech Co. Ltd. 

This article has been supported by an educational grant from Iridex.

References:

1. Tham YC, Li X, Wong TY, et al. Global prevalence of glaucoma and projections of glaucoma burden through 2040: a systematic review and meta-analysis. *Ophthalmology*. 2014;121(11):2081-2090.
2. Butt NH, Ayub MH, Ali MH. Challenges in the management of glaucoma in developing countries. *Taiwan Journal of Ophthalmology*. 2016; 6(3): 119-122.
3. Broadway DC, Chang LP. Trabeculectomy, risk factors for failure and the preoperative state of the conjunctiva. *Journal of glaucoma*. 2001;10(3):237-249.
4. Arjamaa O, Nikinmaa M. Oxygen-dependent diseases in the retina: role of hypoxia-inducible factors. *Exp Eye Res*. 2006;83(3):473-483.
5. Johnstone M, Wang R, Padilla S, Wen K. Transcleral laser induces aqueous outflow pathway motion and reorganization. Presented at the American Glaucoma Society Annual Meeting. March 2, 2017. Coronado, CA.

Going for **Gold** in Macular Intervention

The latest advancements in macular disease treatment may well be worth their weight in gold in the near future

by Hazlin Hassan

Maculopathy is one of the most common causes of blindness. But diseases related to the macula region located within the retina are sometimes difficult to treat.

The latest advancements in macular disease treatment, therefore, may well be worth their weight in gold in the near future. Several surgeons shared promising golden treatments yesterday at the 12th Asia-Pacific Vitreo-retina Society Congress (APVRS 2018) in Seoul, Korea, during a session on the latest advancement in macular intervention.

Gregg Kokame, M.D., from the University of Hawaii John A. Buma School of Medicine, shared on "A New Surgical Therapy for Exudative AMD and PCV with Episcleral Brachytherapy." For exudative age-related macular degeneration (AMD) and polypoidal choroidal vasculopathy (PCV) subtype, the initial treatment of choice is anti-VEGF therapy, he said, noting however that there is a higher prevalence of PCV in anti-VEGF resistant eyes. "Alternative therapies are important to minimize treatment burden, improve visual outcomes and anatomic outcomes," he said. Some of the possible alternative treatments include combining anti-VEGF with steroids, giving more frequent injections, switching to other anti-VEGF agents, and episcleral brachytherapy.

Elliott Sohn, M.D., Associate Professor, and Director of Retina Fellowships at the University of Iowa, presented on

"Instrument Development for Retinal Stem Cell Based Scaffold Transplantation." Patients with inherited retinal diseases start off with relatively mild cell loss in the early stages, but later on in the course of the disease, there may be irreversible vision loss. He shared with delegates an experiment using a scaffold for subretinal cells, instead of bolus or suspension injection.



There is "poor integration when cells are injected as bolus - largely due to efflux and death," he said. The device can successfully implant polymer into large animals, he noted, adding that polymers are well-tolerated in non-immune suppressed large animals with retinal degeneration. The device and polymer have passed FDA required testing to human use, and the device is ready to be used in human clinical trials to treat late stage inherited retinal diseases, he concluded.

Professor Dennis Lam, Chairman and CEO of C-MER International Eye Care Group talked about how to treat the "Refractory Macular Hole."

"In the past, macular hole is considered to be not treatable because

you have lost the most important tissue of the retina," he told delegates, adding that things have changed and the success rate is very high now. "Instead of saying to your patients, sorry we can do nothing, now we want to operate as soon as possible," he emphasized.

However there are some 10-20% of cases involving refractory macular holes where the risk factors include larger holes, high myopia, and previous failed surgeries. Professor Lam shared details of surgeries where he had very successfully applied laser to the base and rim of the macular hole in difficult cases where the patients had a very large macular hole, retinal detachment, high myopia and had had previous failed surgeries.

Young Hee Yoon, M.D., Ph.D., from the Department of Ophthalmology of Asan Medical Center, Seoul, Korea, presented on "Improvement in Visual Function Following Argus II Implantation." The Argus II bionic eye prosthesis works by converting images into pulses of electricity that the brain perceives as patterns of light. She said that Argus II-implanted Korean patients achieved an excellent visual outcome, including letter reading, and independency in orientation and mobility. Careful selection of patients and accurate operative procedures is the key in achieving the optimal effect of this implant, she added. However, patients must be fully committed to undergo visual rehabilitation and training with the implant in order to maximize the ability to use it in daily life. 🌐

Biomarkers and AI will Advance AMD Treatment



Prof. Dr.med. Frank Holz

by John Butcher

Speakers focused on the leading global cause of blindness – age related macular degeneration (AMD) – during an afternoon session at the 12th Asia-Pacific Vitreo-retina Society Congress (APVRS 2018) in Seoul, Korea, yesterday.

Advances can be made, they said, highlighting the need for biomarkers to assist early intervention and the role artificial intelligence (AI) could play in tackling the condition.

Ophthalmologist and AMD researcher, Prof. Dr.med. Frank Holz spoke about Macustar, a European-Union funded research project that is aimed at tackling early stage age-related macular degeneration (AMD).

The project works across multiple sites in Europe, including Moorfields Eye Hospital in London, Radboud University Medical Center in the Netherlands and the University of Bonn's Department of Ophthalmology in Bonn, Germany.

Macustar had made advances in developing structural biomarkers for disease progression, Prof. Holz said, that will enable more tailored treatment and provide valuable information that could be used in conjunction with AI in the tackling of AMD.

Genetics is a factor in developing AMD, according to Prof. Holz, but once a patient has it, genetics has little impact on how the disease develops. There are many potential areas for risk markers in the

progression of AMD, Prof. Holz said. They include lesion and eye-specific prognostic factors such as multilobularity and outer retinal tubulation, as well as fellow-eye specific factors and genetic variants.

He said the Classification of Atrophy Meeting (CAM) had done good work in developing AMD treatment. CAM is a group that consists of retina specialists, image reading center experts, retinal histologists, and optics engineers who aim to develop consensus terminology and criteria for defining atrophy based on OCT findings in the setting of AMD. It has done so by reviewing existing literature, performing masked analysis of longitudinal multimodal imaging for a series of eyes with AMD and reviewing the findings to define areas of agreement and disagreement. Over 12 months, CAM developed a classification system based on OCT for atrophy secondary to AMD.

That system is now used as a "prerequisite for testing novel interventions," said Prof. Holz, and provides a potentially valuable tool for training artificial intelligence.

Once artificial intelligence is introduced more thoroughly into the field of AMD research and treatment, larger amounts of data will be able to be processed and greater speed, allowing for the development of new biomarkers and better treatment as a whole, he added.

Artificial intelligence will be "enormously helpful" in developing treatments for AMD, he said.

Furthermore, Dr. Ryo Kawasaki focused on the prevalence of geographic atrophy in Asian populations, which he has been involved in studying for some time.



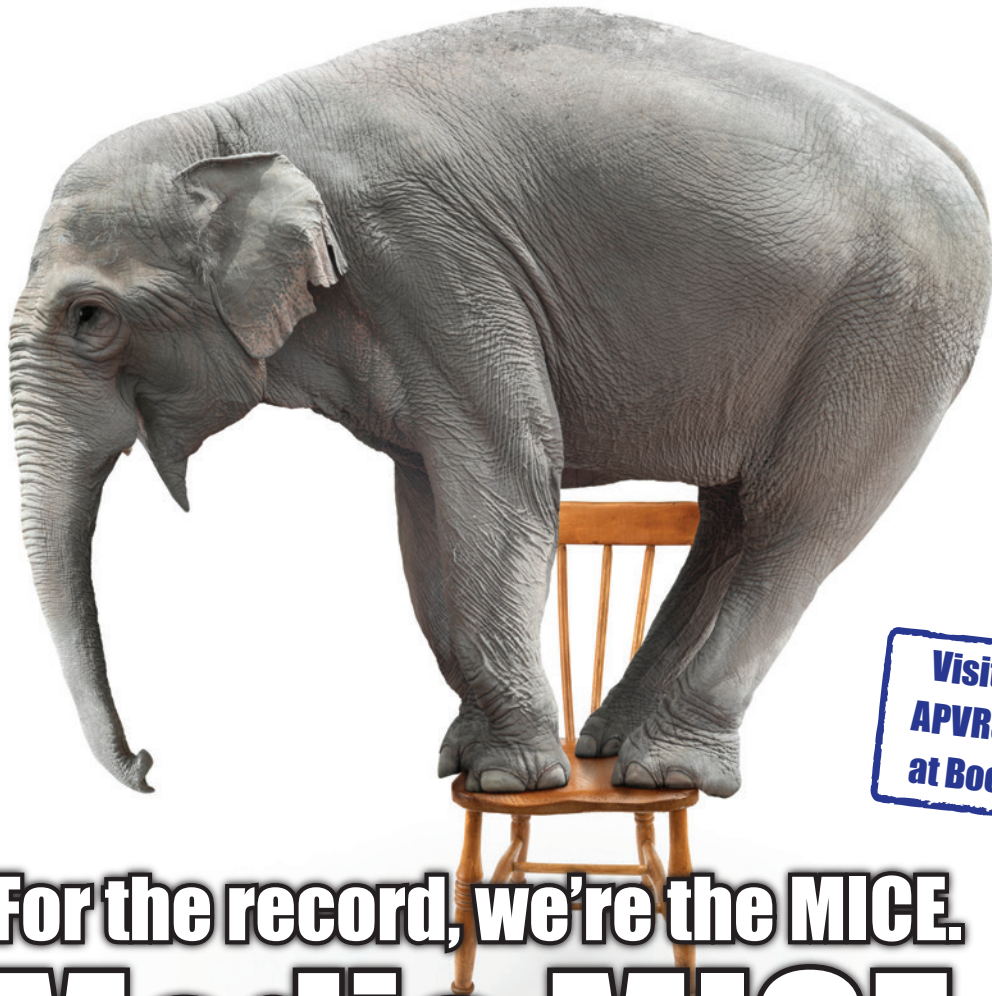Dr. Ryo Kawasaki

Old studies comparing European and Asian populations had found a much higher rate of age-related maculopathy among Europeans, he told the audience, but more recent studies have narrowed the gap, although a significant one still remains in certain areas.

There is a smaller presence of early stage AMD among Asian populations compared with Europeans, mainly driven by the former having lower drusen levels, he said. But in terms of late stage AMD, levels are very similar between Europeans and Asian men.

Asian women, however, show much lower levels of late stage AMD than both their European counterparts and Asian men, he added. AMD among Asians is more often neovascular than GA, he added, probably due to genetic predispositions, higher polypoidal choroidal vasculopathy (PCV) levels in Asian populations and high number of cigarette smokers, which could all be contributing factors. ☺

SOME SAY WE'RE THE ELEPHANT IN THE ROOM



Visit Us at
APVRS 2018
at Booth 63



For the record, we're the MICE. **Media MICE.**

We're not the nicest eye care Media, content marketers and writers.
We are the MICE-est!

For the best, MICE unique eye care Media & medical writers in
Asia-Pacific and globally, email us at enquiry@mediamice.com

What We Do, in the MICE-est of ways:

- Medical Writing
- Manuscript Writing and Editing for Peer-reviewed Journal Submission
- Print or Digital Magazine/ Newsletter Creation
- Social Media Marketing
- Worldwide Symposium/ Conference Coverage
- Content Marketing
- Augmented Reality
- Exhibition Booth Entertainment
- PIE Magazine Advertising and Videos



6001 Beach Road, #19-06 Golden Mile Tower, Singapore 199589

Phone: +65 8186 7677 | U.S.: +1 302 261 5379

E-mail: enquiry@mediamice.com | Web: www.mediamice.com



THIS IS DIGITAL

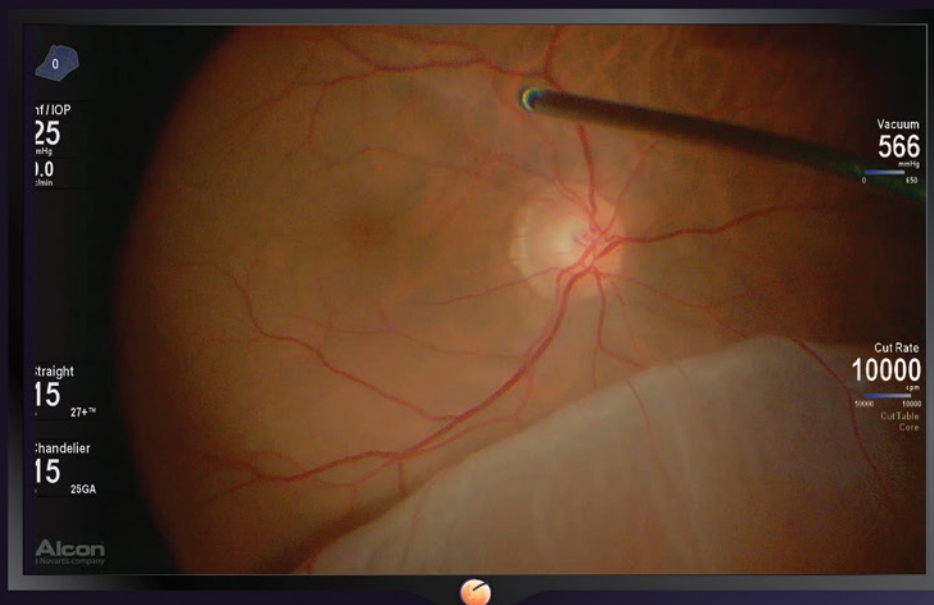
This is

NOENUITY®
DIGITALLY ASSISTED VITREORETINAL SURGERY

High Magnification Performance ¹

Extended Depth of Field¹

Integration with the
CONSTELLATION® Vision System



SEE IT BETTER. DO IT BETTER.

Reference: 1. Alcon Data on File. Yin L, Sarangapani R. Assessment of visual attributes for NOENUITY® 3D Visualization System 1.0 for digitally assisted vitreoretinal surgery. Alcon Modeling and Simulation. January 2016.